

Symptomatic retention of the patency capsule: a multicenter real life case series

Authors

Uri Kopylov^{1,*}, Artur Nemeth^{2,*}, Alba Cebrian³, Gabriele Wurm Johansson², Henrik Thorlacius², Ignacio Fernandez-Urien Sainz³, Anastasios Koulaouzidis⁴, Rami Eliakim¹, Ervin Toth²

Institutions

Institutions are listed at the end of article.

submitted 26. April 2016
accepted after revision
 5. July 2016

Bibliography

DOI <http://dx.doi.org/10.1055/s-0042-112588>
 Published online: 8.8.2016
 Endoscopy International Open 2016; 04: E964–E969
 © Georg Thieme Verlag KG
 Stuttgart · New York
 E-ISSN 2196-9736

Corresponding author

Uri Kopylov, MD
 Department of
 Gastroenterology
 Sheba Medical Center
 Tel Hashomer
 Ramat Gan
 Israel
 Fax: +972-3-53031600
ukopylov@gmail.com

Background and aims: The patency capsule is designed to evaluate the patency of the small bowel before administration of small-bowel capsule endoscopy (SBCE) in patients at high risk of retention. The utilization of a patency capsule may be associated with a risk of symptomatic retention, but very few cases have been reported to date. The aim of our study was to describe our experience with this rare complication of a patency capsule.

Methods: This was a multicenter retrospective case series. The medical records of patients who underwent a patency capsule test were scanned and all cases of symptomatic retention were collected.

Results: In total, 20 symptomatic cases of retention out of 1615 (1.2%) patency capsule tests were identified; in one patient, the patency capsule was retained in the esophagus, in the rest, the capsule was detected in the small bowel resulting in abdominal pain or small-bowel obstruction. One patient (5%) required surgery; all other patients resolved spontaneously or after corticosteroid therapy.

Conclusions: Symptomatic patency capsule retention is a very rare complication with a favorable prognosis. It should be recognized but its use in patients with suspected small-bowel stenosis should not be discouraged.

Introduction

Small-bowel video capsule endoscopy (SBCE) is a prime modality for diagnosis of small-bowel [1–4] pathology such as obscure gastrointestinal bleeding (OGIB), small-bowel tumors and inflammation [5]. It plays an important role in both the diagnosis and monitoring of small-bowel Crohn's disease (CD) [1–8]. However, one of the main limiting factors in the use of SBCE in patients with established CD is the risk of capsule retention, which has been reported to be as high as 13% in early studies [9,10], although in more recent series, the risk of retention was much lower [11–16]. In patients with established CD, assessment of small-bowel patency by cross-sectional imaging or patency capsule is recommended [7]. The patency capsule (Given Imaging, Yokneam, Israel) is a non-diagnostic capsule of the same shape and dimensions as the diagnostic capsule (Fig. 1). The cellophane-walled capsule cylinder, filled with lactose admixed with barium, is protected by hollow plugs allowing influx of

intestinal fluid leading to dissolution of the lactose. In addition to barium which allows radiological detection, the patency capsule contains an inner RFID tag which enables detection by a handheld radiofrequency scanner (HHS) [3]. Successful excretion or non-detectability of the ingested patency capsule in a predefined time (40 hours for the 1st generation and 30 hours for the 2nd generation) patency capsule indicates that a diagnostic SBCE can be safely performed [1,7]. Complications from a patency capsule are very rare; only a handful of cases, presenting with symptoms ranging from mild abdominal pain to full-blown small-bowel obstruction, have been reported to date [8,17–22].

The aim of the current study is to describe our multicenter experience with symptomatic cases of patency capsule retention.

Methods

A retrospective chart review was performed to identify patients with symptomatic patency capsule retention (defined as symptoms of abdominal pain/vomiting) combined with detection of

* These authors contributed equally.

License terms



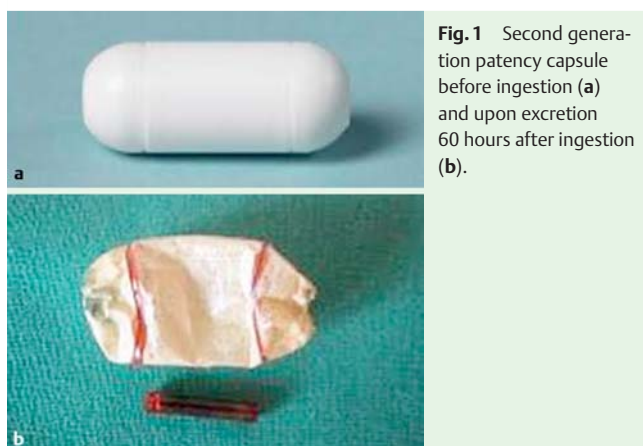

Fig. 1 Second generation patency capsule before ingestion (a) and upon excretion 60 hours after ingestion (b).

the patency capsule in the small bowel by plain abdominal film (XR), computed tomography (CT), or HHS within or after the defined excretion time.

Results

A total of 1615 patency capsule examinations were registered in the clinical databases of the participating centers (between June 2005 and December 2015). In total, 20 cases of symptomatic patency capsule retention were identified (1.2%). In one patient, the patency capsule was retained in the esophagus, while in the rest, it was retained in the small bowel.

The patency capsule examination was performed in 19 patients for suspected (6/20, 30%) or established (13/20, 65%) CD, and in one patient for a suspected mesenteric ischemic event. Six patients (30%) had a previous history of abdominal surgery; 7 (35%) had previous episodes of small-bowel obstruction (SBO); 2 (10%) patients had used nonsteroidal anti-inflammatory drugs (NSAIDs) at least once within the preceding 12 months. Two (10%) of the patients had undergone previous radiotherapy. In one patient, a M2A capsule was used, and in the remainder, the Agile patency capsule was used.

All patients with a retained capsule presented with abdominal pain; in 14 of them (70%), the presentation was accompanied by overt symptoms of clinical small-bowel obstruction (vomiting, abdominal distension, failure to pass stool or gas). The median time from patency capsule ingestion to diagnosis was 9 hours (interquartile range (IQR) 8–24 hours). The patency capsule was detected by HHS in 9 (45%) of the patients; small-bowel location was confirmed by XR (● Fig. 2) and CT (● Fig. 3) in three patients each; in one patient with dysphagia, the patency capsule was detected by HHS and later discovered in the esophagus and advanced to the duodenum by esophagogastroduodenoscopy. In the remainder of the patients, HHS was not used and the patency capsule was detected either by XR or CT directly.

The symptoms resolved spontaneously within up to 72 hours in 13 (65%) patients. Five (20%) patients were treated with systemic corticosteroids with subsequent resolution within up to 1 week. One patient required ileocecal resection and in another, the patency capsule, which was retained in the esophagus due to a Schatzki ring, was advanced to the duodenum endoscopically. This patient underwent diagnostic SBCE (introduced endoscopically) that was normal and uneventful.

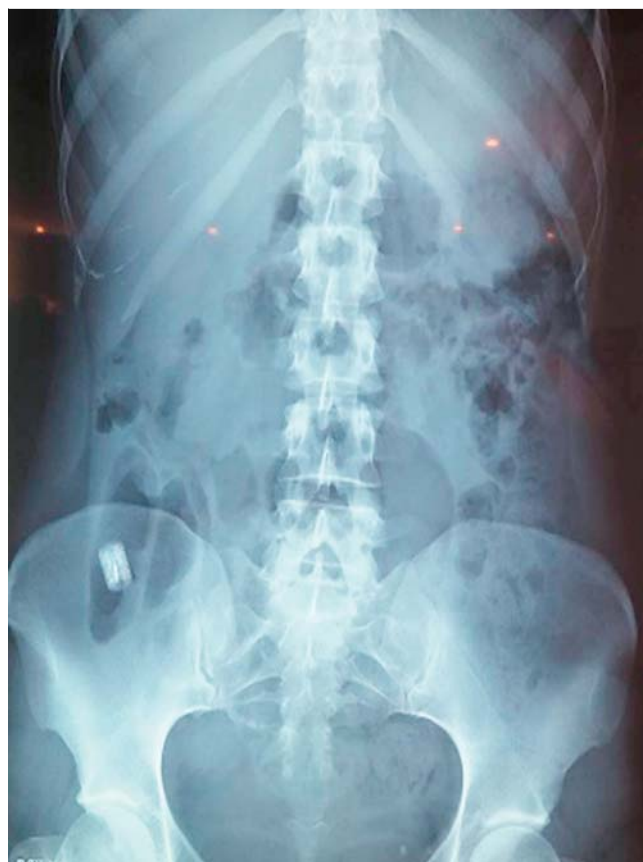

Fig. 2 Plain abdominal X-ray: patency capsule in the right iliac fossa.

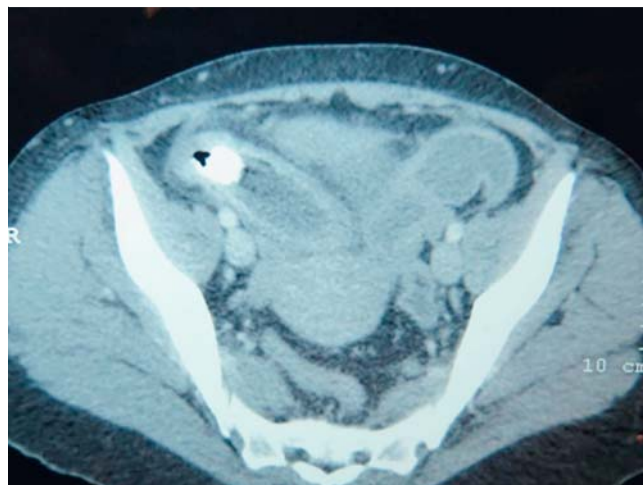


Fig. 3 Abdominal CT: patency capsule in the distal ileum causing an intestinal obstruction.

Subsequent cross-sectional imaging (CT enterography (CTE)/magnetic resonance enterography (MRE)) was performed in 12 (60%) patients; in 10/12 (83%), ileal stenosis was detected. In another two patients, cross-sectional imaging was normal. Patient details and clinical course are described in detail in ● Table 1.

Table 1 Characteristics and clinical course of patients presenting with symptomatic patency capsule retention.

Pa-tient	Age, years	M/F	Patency capsule model	Indication for VCE	Surgical history	History of radiation	History of SB obstruction	Symptoms	Time to presentation, hours	Modality for patency capsule detection	Treatment	Outcome	Subsequent diagnostic findings
1	49	F	M2	Known CD. Reassessment of disease activity	Ileocectomy, 4 SB resections	0	1	Abd. pain, vomiting	50	HHS, XR	CS	Resolution after 2 days	MRE – stenosis in the terminal ileum
2	56	M	Agile	Suspected CD	None	0	1	Abd. pain, nausea	8	HHS, XR	0	Spontaneous resolution	CTE – stenosis in the ileum
3	57	F	Agile	Known CD. Reassessment of disease activity	Colectomy, ileal resection	0	0	Abd. pain	6	HHS	0	Spontaneous resolution	MRE – stenosis in the terminal ileum
4	34	M	Agile	Known CD. Reassessment of disease activity	None	0	0	Abd. pain, vomiting	6	XR	CS	Resolution after 5 days	MRE – stenosis in the terminal ileum
5	25	M	Agile	Known CD. Iron deficiency anemia	None	0	1	Abd. pain, diarrhea	8	HHS, XR	0	Spontaneous resolution	MRE – stenosis in the ileum
6	61	M	Agile	Suspected mesenterial ischemia	Ileal resection	0	1	Abd. pain, vomiting	8	HHS, CT	0	Spontaneous resolution	NA
7	73	F	Agile	Suspected CD (anemia, abd. pain)	Hysterectomy	1	1	Abd. pain, vomiting	24	HHS, CT	0	Spontaneous resolution	CTE – normal, VCE – ileal stenosis
8	47	F	Agile	Suspected CD (anemia, abd. pain)	None	0	0	Abd. pain, nausea	8	HHS, XR	0	Spontaneous resolution	CTE – normal
9	24	F	Agile	Known CD. Reassessment of disease activity	None	0	0	Abd. pain, vomiting	8	CT	CS	Resolution after 7 days	CTE – stenosis in the terminal ileum
10	42	M	Agile	Known CD. Reassessment of disease activity	Laparoscopy	0	0	Abd. pain, vomiting	10	XR	0	Spontaneous resolution	NA
11	52	M	Agile	Known CD. Reassessment of disease activity	None	0	0	Chest pain, dysphagia	0	XR, gastroscopy	Gastroscopy	Successful	VCE – normal, VCE – normal, uneventful
12	68	M	Agile	Known CD. Reassessment of disease activity	None	0	0	Abd. pain	54	HHS, XR	0	Spontaneous resolution	MRE – stenosis in the ileum
13	36	F	Agile	Known CD. Reassessment of disease activity	None	0	0	Ileus	8	Abdominal CT	Ileocecal resection	Resolution after surgery	NA
14	40	M	Agile	Suspected CD. Reassessment of disease activity	None	0	0	Abd. pain, vomiting	16	XR	0	Spontaneous resolution	CTE – stenosis in the terminal ileum
15	25	F	Agile	Known CD. Reassessment of disease activity	None	0	0	Abd. pain, obstruction	12	XR	0	Spontaneous resolution	NA
16	49	F	Agile	Suspected CD	None	0	0	Abd. pain, distension	24	XR, CT	Nasogastric tube, CS	Resolution after 3 days	CTE – inflammatory stenosis in the ileum
17	79	F	Agile	Suspected CD	Anterior resection of the rectum	1	0	Abd. pain, vomiting	36	XR	0	Spontaneous resolution – 2 days	Ileocolonoscopy – normal (resulted in perforation)
18	42	M	Agile	Known CD. Reassessment of disease activity	None	0	1	Abd. pain, distension	12	XR	0	Spontaneous resolution – 2 days	NA
19	47	F	Agile	Suspected CD	None	0	1	Abd. pain, vomiting	24	CT	CS	Resolution in 2 days	CT – stenosis in the ileum
20	39	F	Agile	Known CD. Reassessment of disease activity	None	0	0	Abd. pain, vomiting	6	XR	CS	Resolution in 2 days	NA

F, female; M, male; CD, Crohn's disease; Abd., abdominal; HHS, hand-held scanner; XR, plain abdominal film; CT, computed tomography; CS, corticosteroids; VCE, video capsule endoscopy; SB, small bowel; CTE, CT enterography; MRE, magnetic resonance enterography.

Table 2 Adverse effects of the patency capsule in the literature.

Reference	Model of patency capsule	Design	Patients presenting with abdominal pain	Adverse events	Clinical small-bowel obstruction	Treatment
Spada et al. [22]	1st generation	Prospective	6/34 (17.64%)	Mild: 5/34 (14.71%) Moderate: 0/34 (0%) Severe: 1/34 (2.94%)	1/34 (2.9%)	Spontaneous recovery: 5/34 (14.71%) Medical therapy: 1/34 (2.94%) Surgery: 0/34 (0%)
Boivin et al. [25]	1st generation	Prospective	6/22 (27.27%)	Mild: 1/22 (4.54%) Moderate: 1/22 (4.54%) Severe: 4/22 (18.18%)	NA	Spontaneous recovery or medical therapy: 5/22 (22.73%) Surgery: 1/22 (4.54%)
Delvaux et al. [21]	1st generation	Prospective	3/22 (13.64%)	Mild: 1/22 (4.54%) Moderate: 0/22 (0%) Severe: 2/22 (9.09%)	3/22 (13.6%)	Spontaneous recovery: 1/22 (4.54%) Medical therapy: 0/22 (0%) Surgery: 2/22 (9.09%)
Signorelli et al. [26]	Agile	Prospective	2/32 (6.25%)	Mild: 2/32 (1.44%) Moderate: 0/32 (0%) Severe: 0/32 (0%)	0	Spontaneous recovery: 2/32 (1.44%) Medical therapy: 0/32 (0%) Surgery: 0/32 (0%)
Banerjee et al. [27]	1st generation	Prospective	0/26	None	0	
Spada et al. [28]	2nd generation	Prospective	6/27 (22.22%)	Mild: 5/27 (18.52%) Moderate: 0/27 (0%) Severe: 1/27 (3.70%)	1/27 (3.7%)	Spontaneous recovery or medical therapy: 5/27 (18.52%) Surgery: 1/27 (3.70%)
Herrerias et al. [19]	Agile	Prospective	17/106 (16%)	Mild: 3/106 (2.8%) Moderate: 11/106 (10.4%) Severe: 3/106 (2.8%)	1/106 (0.9%)	Spontaneous recovery or medical therapy: 16/107 (15.1%) Surgery: 1/106 (0.9%)
Postgate et al. [29]	Both generations	Retrospective	0/58			
Cohen et al. [30]	2nd generation	Prospective	0/18			
Yadav et al. [31]	2nd generation	Prospective	0/42			
Shiotani et al. [32]	2nd generation	Prospective	0/52			
Nakamura et al. [33]	2nd generation	Retrospective	0/100			
Assadsangabi et al. [34]	2nd generation	Prospective	Adverse effects not reported			
Rommele et al. [35]	2nd generation	retrospective	0/38			
Albuquerque et al. [36]	2nd generation	Prospective	0/52			
Total			40/629 (6.3%)			Surgery: 5/629 (0.8%)

Discussion

The patency capsule is an important tool for assessment of small-bowel patency in patients who are at high risk of capsule retention. Utilization of a patency capsule may significantly reduce the risk of SBCE retention [22]. The latest patency capsule model (Agile) was designed to minimize the occurrence of abdominal pain secondary to non-extraction of the patency capsule; the dissolution time of the Agile patency capsule is shorter (30 vs 40 hours) due to the presence of two timer plugs instead of one as designed for the first generation patency capsule, allowing an enhanced contact with intestinal secretions as well as shrinkage of both sides minimizing the chance of obstruction. Complications with a patency capsule are rare and usually manifest as abdominal pain with rare cases of overt bowel obstruction [17–20]. We collected the results of the available prospective studies and case series pertaining to the use of a patency capsule (Table 2). The pooled rate of patency capsule-related complications was 40/629 (6.3%). The retention resolved spontaneously in 35/40 patients (87.5%); five patients (12.5%) required surgery. In addition to abdominal pain and small-bowel obstruction, a single case of intestinal ischemia [23] after patency capsule ingestion was described.

The most probable explanation for patency capsule complications is lodgment of the capsule in a strictured segment of the small bowel, resulting in pain and partial obstruction. In most cases, the capsule dissolves upon contact with intestinal fluids and passes by itself; however, in some cases, such contact may be limited leading to slower dissolution, or even failure to completely dissolve.

The current study is the largest real life case series describing symptomatic patency capsule retention. Almost all of our cases were patients with suspected or established CD. The prevalence of this adverse event was very low. Significant ileal stenosis was demonstrated on cross-sectional imaging in most of the patients. In all but one patient, symptoms resolved without the need for surgery or endoscopy, most probably after patency capsule dissolution. Interestingly, two patients did not have any evidence of small-bowel stenosis on cross-sectional imaging. As these patients were symptomatic and presented with a suspected bowel obstruction, this most probably reflects the limitation of cross-sectional imaging for prediction of capsule retention [24,25]. The rate of symptomatic patency capsule retention in our series is the lowest reported even when compared to earlier prospective series, most probably due to the retrospective nature of our

series that focused on serious adverse events requiring hospitalization. Importantly, even in these severe cases, surgery was required in only one single patient (0.6% of all evaluated patients), obstruction usually resolving spontaneously or with corticosteroid treatment in the majority of cases. One may argue that cross-sectional imaging is safer in comparison to a patency capsule to evaluate small-bowel patency, but it is significantly less accurate in the evaluation of functional small-bowel patency, frequently overestimating the risk of obstruction. In a recent study evaluating the accuracy of MRE for prediction of patency capsule retention in patients with established small-bowel CD, the sensitivity and specificity of MRE were 92.3% and 59%, respectively [24]. Thus, if the decision to administer SBCE had been based on imaging and not patency capsule results, at least 40% of the patients would have been denied the procedure.

Our study has several limitations. First, this was a retrospective multicenter study. The description of the clinical presentation is limited to the description as presented in the clinical charts at the time. Furthermore, we did not use a quantitative pain evaluation scale. Also, we did not document the shape of the patency capsule on expulsion. Moreover, cross-sectional imaging following patency capsule retention was not routinely available in all patients.

In conclusion, symptomatic patency capsule retention is a very rare adverse event that resolves without surgical or endoscopic intervention in the vast majority of cases. This rare complication should be recognized and acknowledged, but should not discourage physicians from utilization of the patency capsule in patients with suspected small-bowel stenosis before administering SBCE.

Competing interests: Uri Kopylov, Artur Nemeth – none. Anastasios Koulaouzidis – ESGE Given Imaging research grant 2011, Lecture honoraria from Dr Falk Pharma, Travel grant/support from Dr Falk Pharma, Abbott, MSD, Ferring, and material support for research from SynMed UK. Ervin Toth, Rami Eliakim – consulting/speaker's fee from Given Imaging. Ignacio Fernandez-Urien Sainz – consulting fee from Medtronic.

Institutions

¹ Department of Gastroenterology, Chaim Sheba Medical Center, Sackler School of Medicine, Tel-Aviv University, Tel-Aviv, Israel

² Department of Gastroenterology, Skåne University Hospital, Malmö, Lund University, Sweden

³ Department of Gastroenterology – NHC, Pamplona, Spain

⁴ Endoscopy Unit, Centre for Liver and Digestive Disorders, The Royal Infirmary of Edinburgh, Scotland, UK

References

- Pennazio M, Spada C, Eliakim R et al. Small-bowel capsule endoscopy and device-assisted enteroscopy for diagnosis and treatment of small-bowel disorders: European Society of Gastrointestinal Endoscopy (ESGE) Clinical Guideline. *Endoscopy* 2015; 47: 352–376
- Kopylov U, Yablecovitch D, Lahat A et al. Detection of small bowel mucosal healing and deep remission in patients with known small bowel Crohn's disease using biomarkers, capsule endoscopy, and imaging. *Am J Gastroenterol* 2015; 110: 1316–1323
- Kopylov U, Ben-Horin S, Seidman EG et al. Video capsule endoscopy of the small bowel for monitoring of Crohn's disease. *Inflamm Bowel Dis* 2015; 21: 2726–2735
- Greener T, Klang E, Yablecovitch D et al. The impact of magnetic resonance enterography and capsule endoscopy on the re-classification of disease in patients with known Crohn's disease: A prospective Israeli IBD Research Nucleus (IIRN) study. *J Crohns Colitis* 2016; 10: 525–531
- Kopylov U, Seidman EG. Clinical applications of small bowel capsule endoscopy. *Clin Exp Gastroenterol* 2013; 6: 129–137
- Cave D, Legnani P, de Franchis R et al. ICCE consensus for capsule retention. *Endoscopy* 2005; 37: 1065–1067
- Annese V, Daperno M, Rutter MD et al. European evidence based consensus for endoscopy in inflammatory bowel disease. *J Crohns Colitis* 2013; 7: 982–1018
- Nemeth A, Kopylov U, Koulaouzidis A et al. Use of patency capsule in patients with established Crohn's disease. *Endoscopy* 2016; 48: 373–379
- Mow WS, Lo SK, Targan SR et al. Initial experience with wireless capsule enteroscopy in the diagnosis and management of inflammatory bowel disease. *Clin Gastroenterol Hepatol* 2004; 2: 31–40
- Cheifetz AS, Kornbluth AA, Legnani P et al. The risk of retention of the capsule endoscope in patients with known or suspected Crohn's disease. *Am J Gastroenterol* 2006; 101: 2218–2222
- Kopylov U, Nemeth A, Koulaouzidis A et al. Small bowel capsule endoscopy in the management of established Crohn's disease: Clinical impact, safety, and correlation with inflammatory biomarkers. *Inflamm Bowel Dis* 2015; 21: 93–100
- Niv E, Fishman S, Kachman H et al. Sequential capsule endoscopy of the small bowel for follow-up of patients with known Crohn's disease. *J Crohns Colitis* 2014; 8: 1616–1623
- Hall BJ, Holleran GE, Smith SM et al. A prospective 12-week mucosal healing assessment of small bowel Crohn's disease as detected by capsule endoscopy. *Eur J Gastroenterol Hepatol* 2014; 26: 1253–1259
- Hall B, Holleran G, Chin JL et al. A prospective 52 week mucosal healing assessment of small bowel Crohn's disease as detected by capsule endoscopy. *J Crohns Colitis* 2014; 8: 1601–1609
- Flamant M, Trang C, Maillard O et al. The prevalence and outcome of jejunal lesions visualized by small bowel capsule endoscopy in Crohn's disease. *Inflamm Bowel Dis* 2013; 19: 1390–1396
- Esaki M, Matsumoto T, Watanabe K et al. Use of capsule endoscopy in patients with Crohn's disease in Japan: a multicenter survey. *J Gastroenterol Hepatol* 2014; 29: 96–101
- Caunedo-Alvarez A, Romero-Vazquez J, Herreras-Gutierrez JM. Patency and Agile capsules. *World J Gastroenterol* 2008; 14: 5269–5273
- Kato S, Osada H, Yakabi K. A rare case of temporary intestinal obstruction induced by the novel tag-less Agile patency capsule in a patient with Crohn's disease. *Dig Endosc* 2016; 28: 481
- Herreras JM, Leighton JA, Costamagna G et al. Agile patency system eliminates risk of capsule retention in patients with known intestinal strictures who undergo capsule endoscopy. *Gastrointest Endosc* 2008; 67: 902–909
- Liatsos C, Kyriakos N, Panagou E et al. An unusual presentation of obstructive ileus, due to impacted Agile patency capsule, in a patient with Crohn's disease. *Ann Gastroenterol* 2011; 24: 65–66
- Delvaux M, Ben Soussan E, Laurent V et al. Clinical evaluation of the use of the M2A patency capsule system before a capsule endoscopy procedure, in patients with known or suspected intestinal stenosis. *Endoscopy* 2005; 37: 801–807
- Spada C, Spera G, Riccioni M et al. A novel diagnostic tool for detecting functional patency of the small bowel: the Given patency capsule. *Endoscopy* 2005; 37: 793–800
- Okoli A, Ammannagari N, Mazumder M et al. When the dissolvable does not dissolve: an agile patency capsule mystery. *Am J Gastroenterol* 2014; 109: 605–607
- Rozendorn N, Klang E, Lahat A et al. Prediction of patency capsule retention in known Crohn's disease patients using magnetic resonance imaging. *Gastrointest Endosc* 2016; 83: 182–187
- Boivin ML, Lochs H, Voderholzer WA. Does passage of a patency capsule indicate small-bowel patency? A prospective clinical trial *Endoscopy* 2005; 37: 808–815
- Signorelli C, Rondonotti E, Villa F et al. Use of the Given Patency System for the screening of patients at high risk for capsule retention. *Dig Liver Dis* 2006; 38: 326–330
- Banerjee R, Bhargava P, Reddy P et al. Safety and efficacy of the M2A patency capsule for diagnosis of critical intestinal patency: results of a prospective clinical trial. *J Gastroenterol Hepatol* 2007; 22: 2060–2063
- Spada C, Shah SK, Riccioni ME et al. Video capsule endoscopy in patients with known or suspected small bowel stricture previously tested with the dissolving patency capsule. *J Clin Gastroenterol* 2007; 41: 576–582
- Postgate AJ, Burling D, Gupta A et al. Safety, reliability and limitations of the given patency capsule in patients at risk of capsule retention: a 3-year technical review. *Dig Dis Sci* 2008; 53: 2732–2738

- 30 Cohen SA, Gralnek IM, Ephrath H et al. The use of a patency capsule in pediatric Crohn's disease: a prospective evaluation. *Dig Dis Sci* 2011; 56: 860–865
- 31 Yadav A, Heigh RI, Hara AK et al. Performance of the patency capsule compared with nonenteroclysis radiologic examinations in patients with known or suspected intestinal strictures. *Gastrointest Endosc* 2011; 74: 834–839
- 32 Shiotani A, Hata J, Manabe N et al. Clinical relevance of patency capsule combined with abdominal ultrasonography to detect small bowel strictures. *Eur J Gastroenterol Hepatol* 2014; 26: 1434–1438
- 33 Nakamura M, Hirooka Y, Yamamura T et al. Clinical usefulness of novel tag-less Agile patency capsule prior to capsule endoscopy for patients with suspected small bowel stenosis. *Dig Endosc* 2015; 27: 61–66
- 34 Assadsangabi A, Blakeborough A, Drew K et al. Small bowel patency assessment using the patency device and a novel targeted (limited radiation) computed tomography-based protocol. *J Gastroenterol Hepatol* 2015; 30: 984–989
- 35 Rommele C, Brueckner J, Messmann H et al. Clinical experience with the PillCam patency capsule prior to video capsule endoscopy: a real-world experience. *Gastroenterol Res Pract* 2016; 2016: 9657053 (Epub 2016 Jan 6) DOI 10.1155/2016/9657053
- 36 Albuquerque A, Cardoso H, Marques M et al. Predictive factors of small bowel patency in Crohn's disease patients. *Rev Esp Enferm Dig* 2016; 108: 65–70